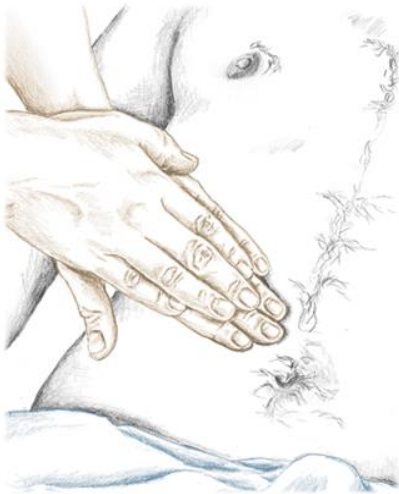

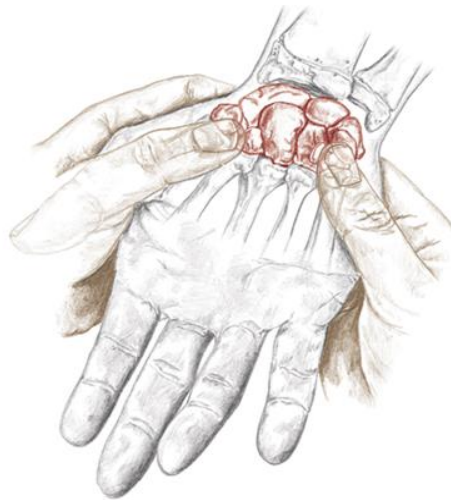
# Palpation Hints

## Making Contact

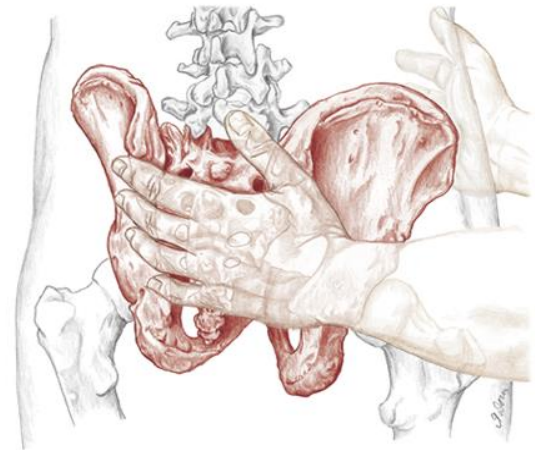
Add Text Here.



**0.3** A firm top hand and a soft bottom hand



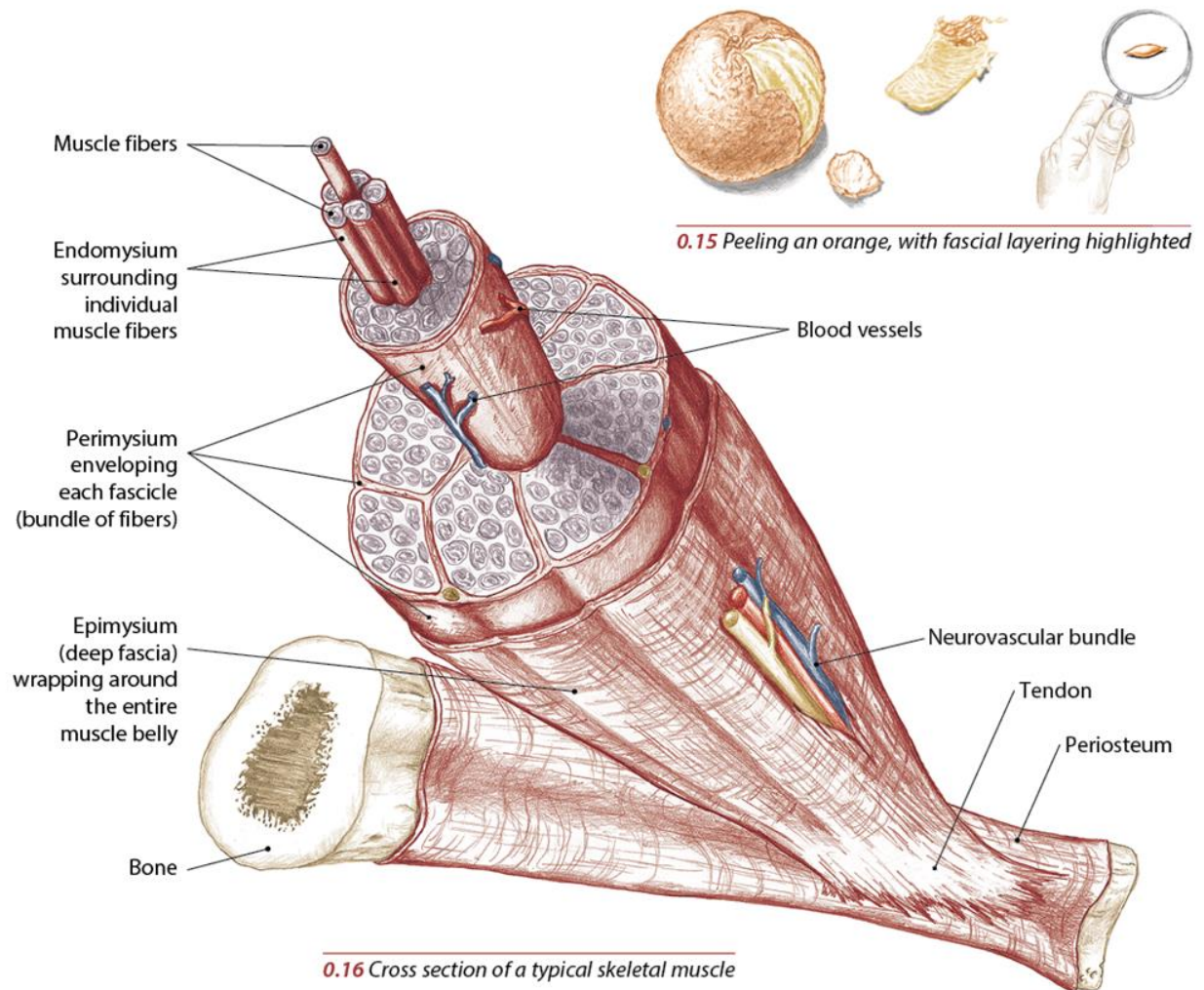
**0.4** Using your thumbpads to explore the small carpal bones in the wrist



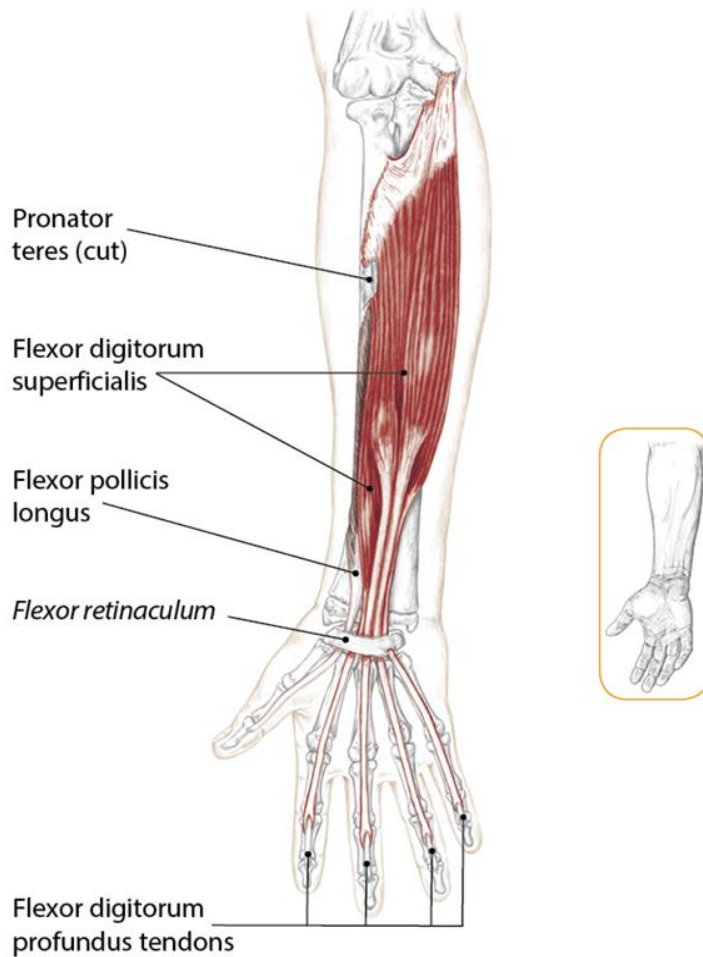
**0.5** Using your entire hand to palpate the pelvis and sacrum

# Muscle

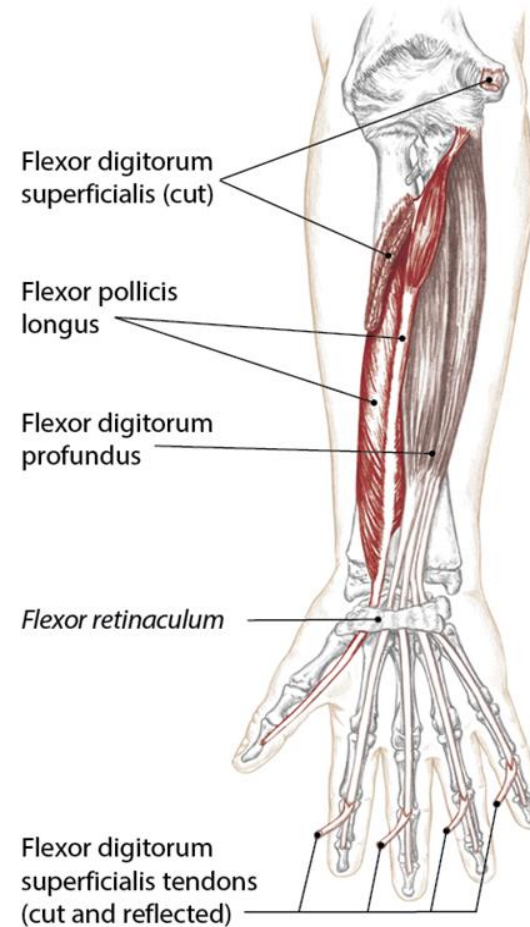
Add Text Here.



# Muscles of the Forearm and Hand



**3.50** Anterior view of right forearm and hand showing intermediate layer of muscles



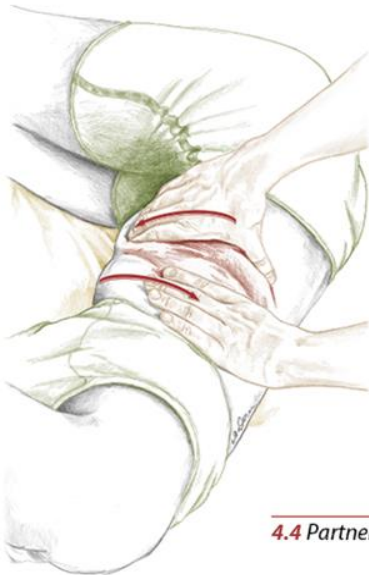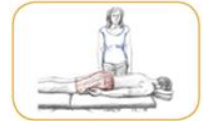**3.51** Anterior view of right forearm and hand showing deep layer of muscles

# Exploring the Skin and Fascia

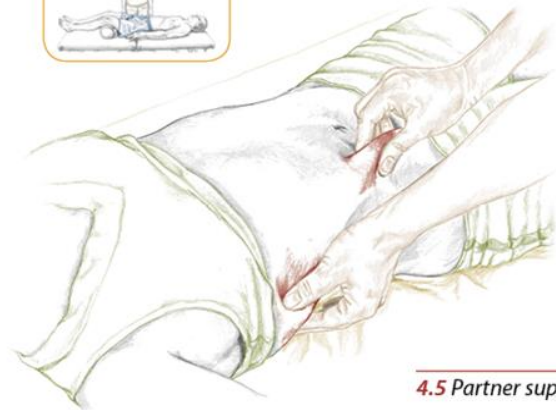
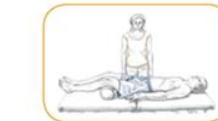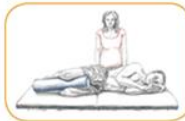Add Text Here.



4.3 Partner prone



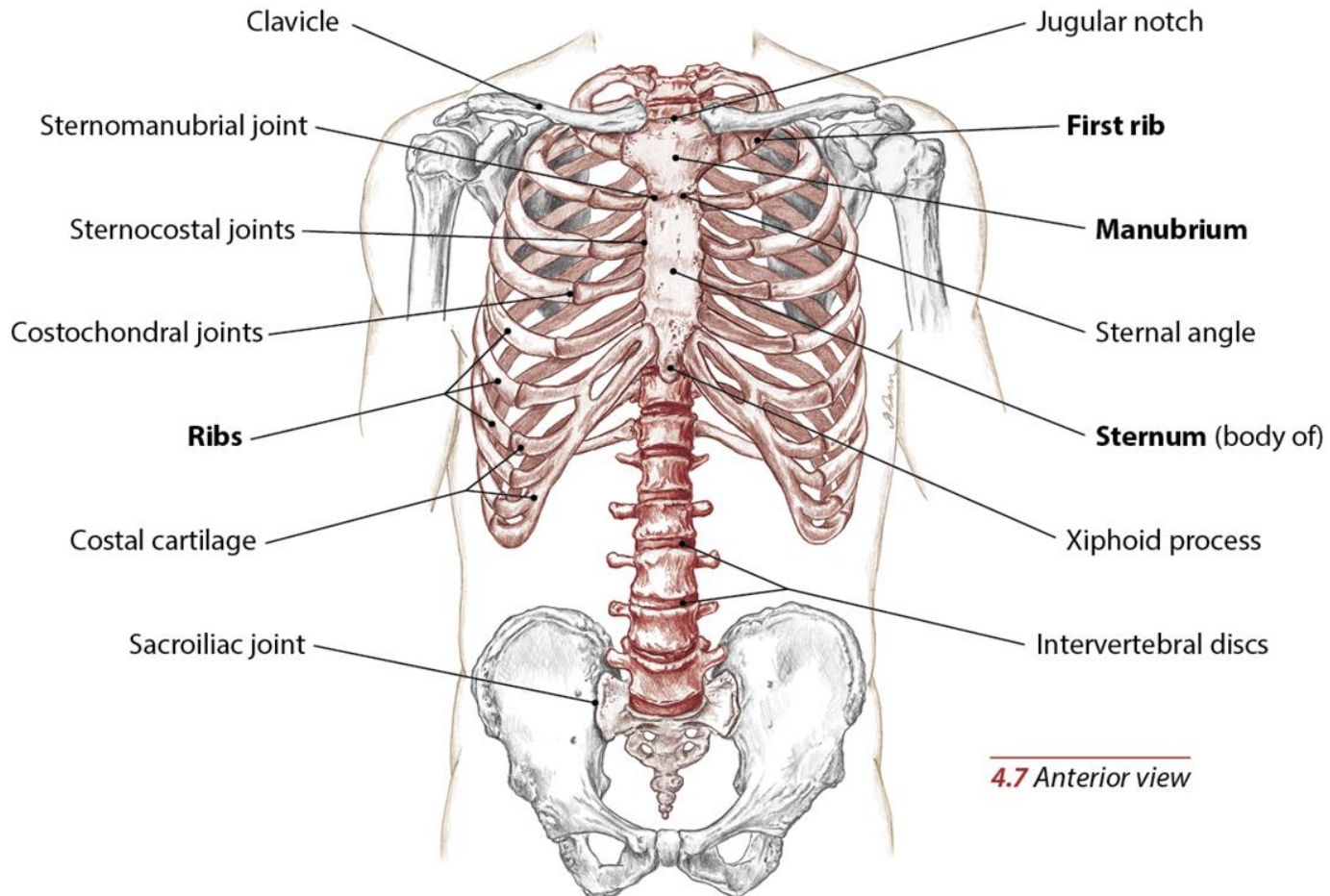
4.4 Partner side lying



4.5 Partner supine

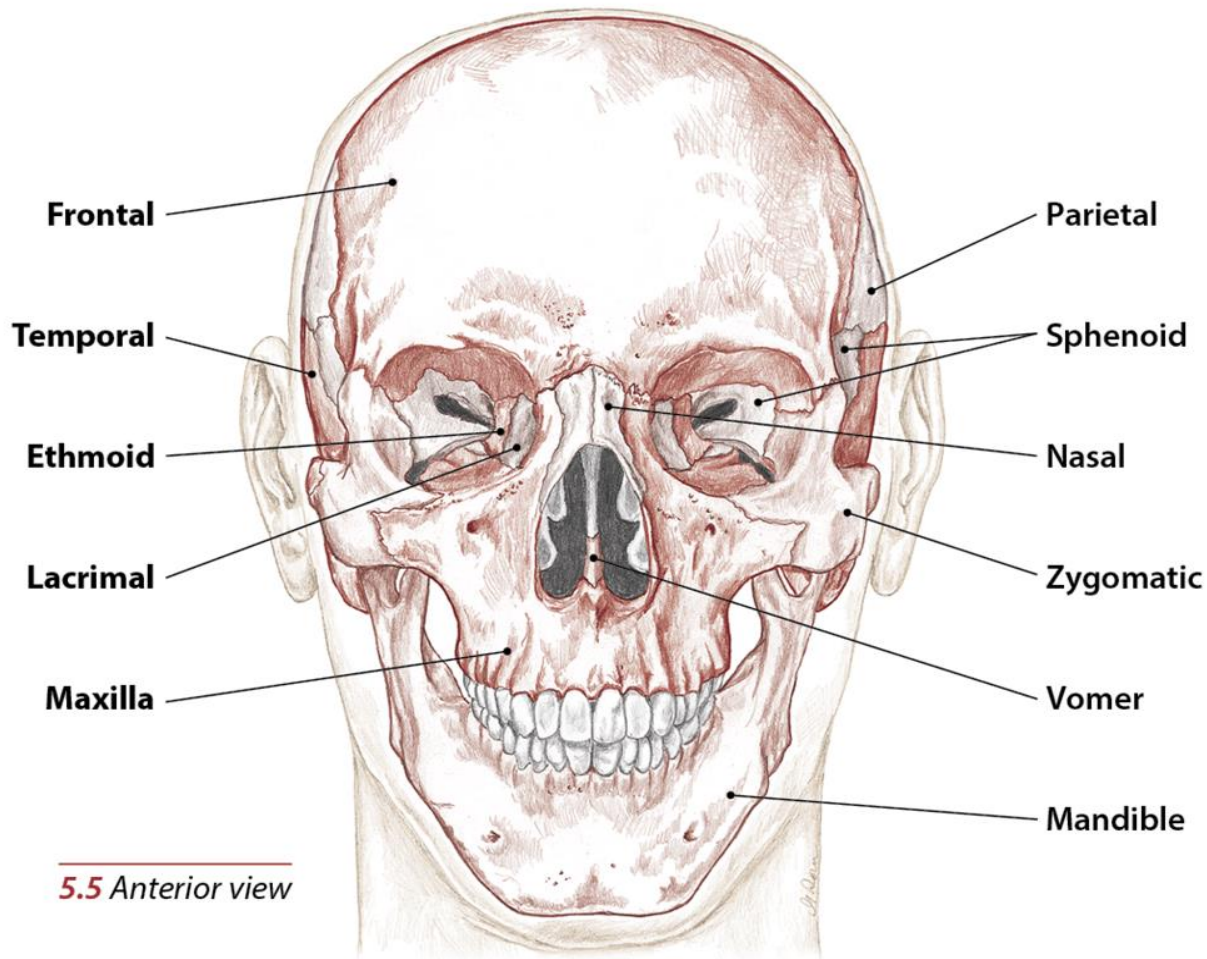


# Bony Landmarks

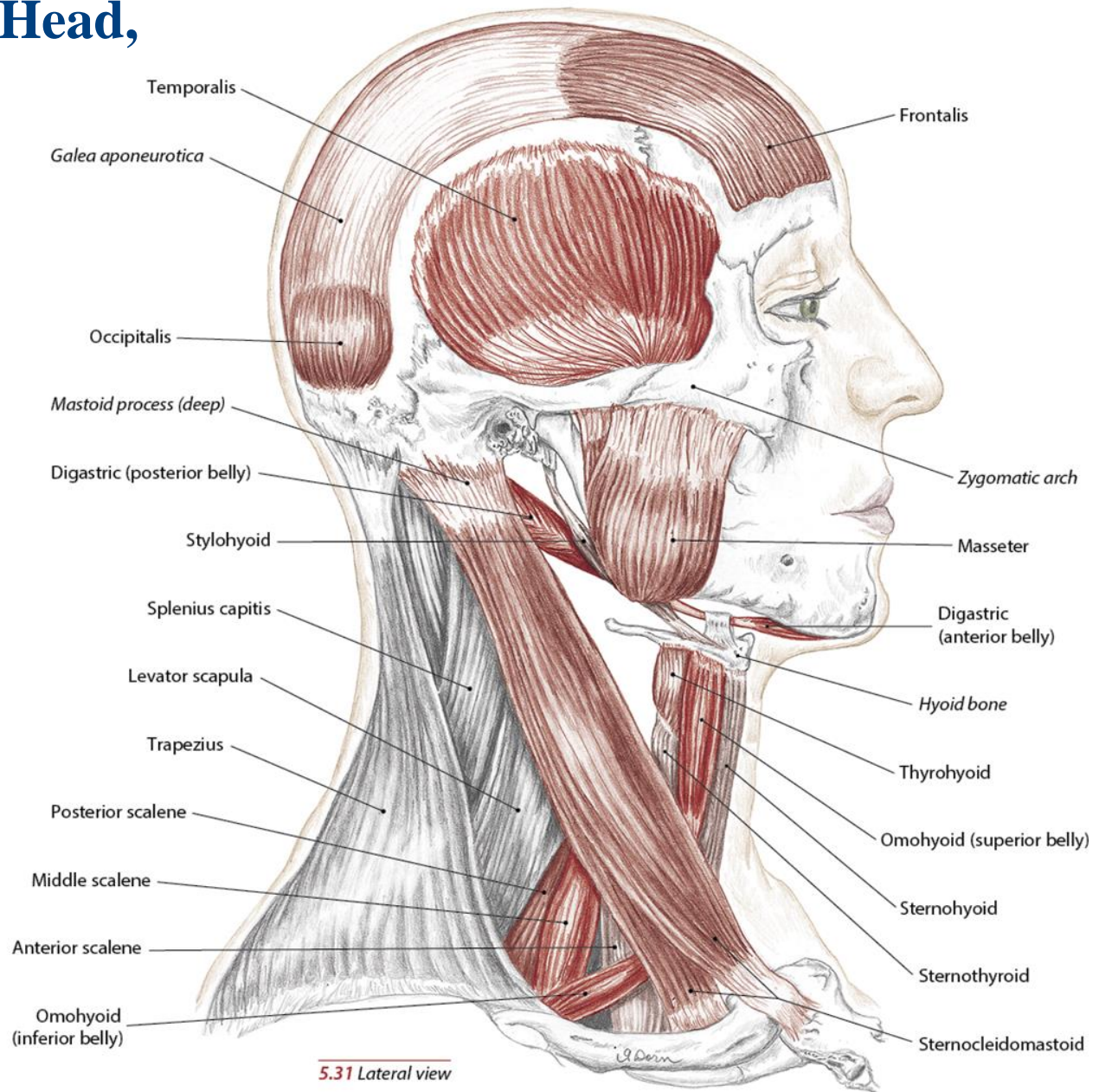


**4.7** Anterior view

# Bones and Bony Landmarks of the Head, Neck and Face

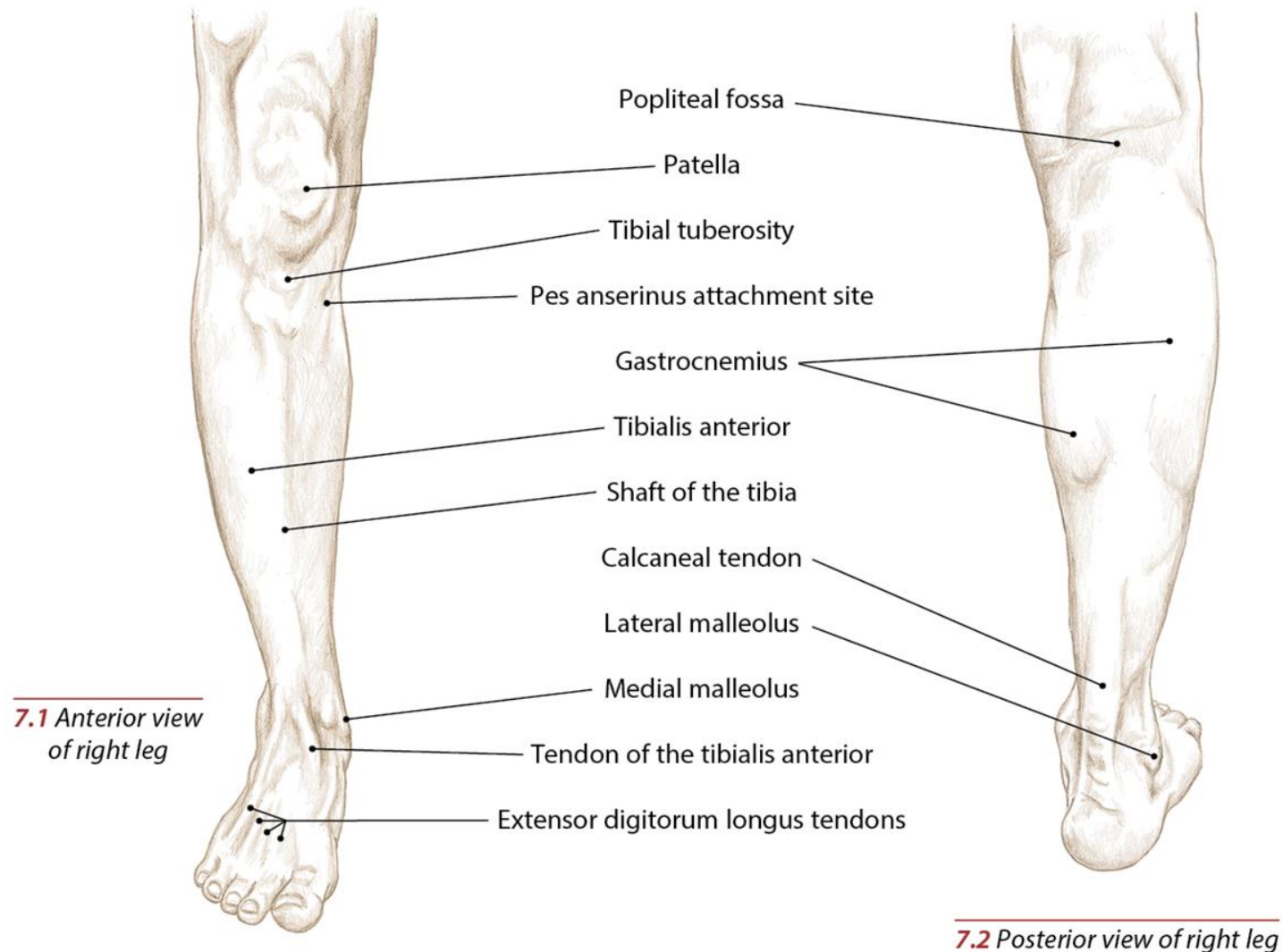


# Muscles of the Head, Neck and Face





# Topographical Views



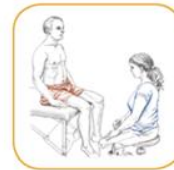

# Tibial Tuberosity and Shaft of the Tibia

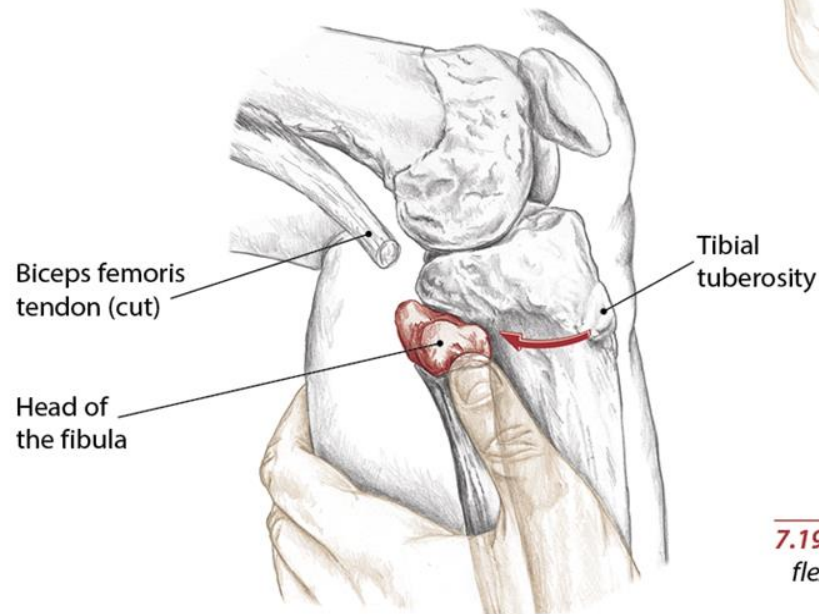
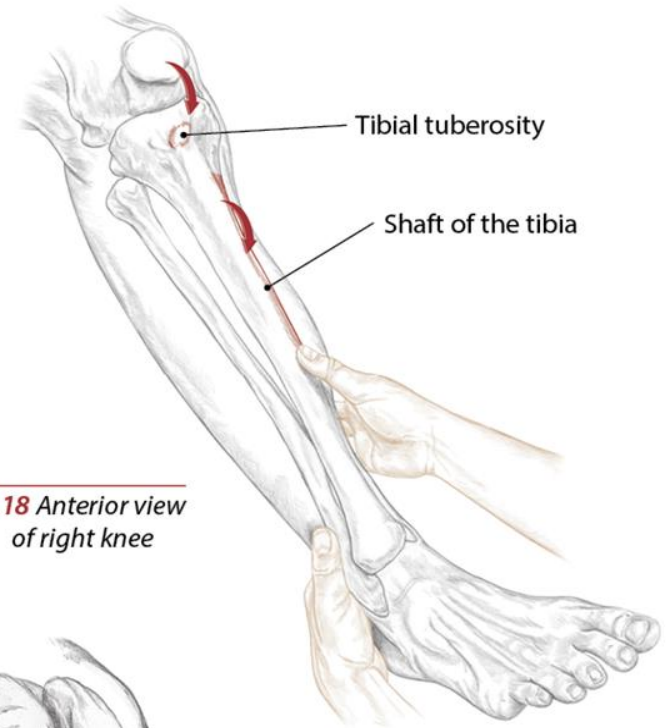
Add Text Here.

## Head of the Fibula

Add Text Here.



**7.18** Anterior view  
of right knee



**7.19** Lateral view of  
flexed right knee

# Blank Slide

Add Text Here.